

# Laser therapy of acute and chronic maxillary sinusitis

Alexey N. Bashkatov<sup>\*a)</sup>, Elina A. Genina<sup>a)</sup>, Elena E. Chikina<sup>b)</sup>, Igor V. Meglinski<sup>c)</sup>, Valery V. Tuchin<sup>a)</sup>, Anatoly B. Knyazev<sup>b)</sup> and Oleg V. Mareev<sup>b)</sup>

<sup>a)</sup> Department of Optics and Biomedical Physics of Saratov State University,  
410012, 83 Astrakhanskaya str., Saratov, Russia;

<sup>b)</sup> Department of Otolaryngology of Saratov State Medical University,  
410012, 112 B. Kazachya str., Saratov, Russia

<sup>c)</sup> School of Mechanical Engineering, Cranfield University, Cranfield, MK43 0AL, UK

## ABSTRACT

The clinical results of photodynamic therapy of maxillary sinusitis have been presented. 0.1%-Methylene Blue aqueous solution in combination with He-Ne laser irradiation (632.8 nm) has been used for treatment of patients with acute and chronic maxillary sinusitis. Efficacy of the photodynamic therapy was estimated with the use of the following criteria: the state of respiration, olfaction, duration of purulent discharge, reconstruction of transport function of ciliary epithelium, etc. The obtained results have shown that the photodynamic therapy is effective in comparison with conservative methods of treatment of the diseases.

**Keywords:** medical optics and biotechnology, clinical applications, otolaryngology, photodynamic therapy, Methylene blue, acute and chronic maxillary sinusitis, He-Ne laser irradiation

## 1. INTRODUCTION

Recently, photodynamic therapy (PDT) is a widespread method in the modern medicine. It is successfully used for treatment of various diseases, including oncological<sup>1,2</sup>, gynecologic<sup>3,4</sup>, dermatological<sup>5-8</sup> ones and the others. The problem of treatment of maxillary sinusitis remains important in rhinology despite wide application of novel pharmaceutical and surgical methods of treatment of the disease. However, only a few reports of application of photodynamic therapy for treatment of rhinological diseases are available.<sup>9</sup>

Development of the novel photodynamic methods includes knowledge of photosensitizers diffusion rate, choice of laser source and optimal conditions for the laser irradiation and delivering the photosensitizers into human tissue. We have presented optical properties of human mucous tissue and Methylene Blue (MB) diffusion coefficient in the tissue earlier.<sup>10</sup> Methylene Blue and He-Ne laser are very appropriate as a photosensitizer and light source due to their biocompatibility and low cost. There are numerous investigations related to application of MB in photodynamic therapy of different diseases.<sup>11-13</sup> However, the use of MB-laser therapy for the treatment of patients with maxillary sinusitis is not presented now.

In this study, for the first time we present the clinical results of administration of Methylene Blue in combination with He-Ne laser irradiation (632.8 nm) for photodynamic therapy of patients with acute and chronic maxillary sinusitis.

## 2. MATERIALS AND METHODS

### 2.1 Patient selection

140 patients of both sexes (ages from 20 to 41 years) with acute and chronic maxillary sinusitis were enrolled for the study. 65 patients were diagnosed as having acute maxillary sinusitis and 75 patients were diagnosed as having chronic

---

\* [bash@optics.sgu.ru](mailto:bash@optics.sgu.ru)

maxillary sinusitis. Diagnosis of all patients was confirmed by X-ray method. Separation of the patients was carried out in accordance with classification of Piskunov et al.<sup>14</sup> All patients had rhinosinusitis.

Patients with acute maxillary sinusitis were separated in two groups in dependence of treatment protocol: I group – 30 patients were treated with photodynamic therapy and II group (the control group) - 35 patients were treated by traditional (pharmaceutical) therapy.

Patients with chronic maxillary sinusitis were also separated in two groups: I group – 35 patients were treated with photodynamic therapy and II group (the control group) - 40 patients were treated by traditional (pharmaceutical) therapy.

Distribution on age and sex of patients with acute and chronic maxillary sinusitis, treated by various methods is presented in table 1.

Table 1. Distribution on age and sex of patients with acute and chronic maxillary sinusitis

Age	Acute maxillary sinusitis						Chronic maxillary sinusitis					
	I group (PDT)			II group (control)			I group (PDT)			II group (control)		
	M	F	%	M	F	%	M	F	%	M	F	%
<b>until 20</b>	2	2	13,3	5	5	10	4	3	20	5	3	20
<b>21-30</b>	5	4	30	4	5	9	6	5	31,4	8	7	37,5
<b>31-40</b>	5	5	33,3	7	4	11	6	7	37,1	6	8	35
<b>older 40</b>	3	4	23,4	4	1	5	3	1	11,5	1	2	7,5
<b>Total:</b>	15	15	100	20	15	35	19	16	100	20	20	100

Patients were excluded if they had surgery treatment of maxillary sinuses before the photodynamic or pharmaceutical therapy. All patients gave their formal consent for participation in the study.

## 2.2 Microbiological examination

Bacteriological examination was carried out to define etiology of pathological process in maxillary sinus. At the anterior rhinoscopy smear was taken from medial nasal duct by sterile tampon. Anesthesia of mucous membrane was not made. Then at topical anesthesia with 10%-lidocaine solution the puncture of maxillary sinus was made with standard method and discharge sampling was taken by sterile syringe. The samples were put into test-tube with meat infusion broth. The obtained material was diluted 1:9 and inoculated on Petri dishes. As a nutrient medium at the bacterial inoculation 5%-blood agar medium was used. The samples were put into thermostat with temperature 37°C for 24 hours. Microbiological examinations were taken before and after the treatment.

## 2.3 Pharmaceutical therapy protocol

The control groups took traditional therapy including antibiotic therapy - intramuscular injections of lincomycin (0.6-0.9 g/day). To obtain high concentration of drugs in the nidus of inflammation, lavage of maxillary sinuses with solutions of antibacterial drugs and physiotherapeutic methods of treatment were carried out. Course of treatment was 5-7 days for the patients with acute maxillary sinusitis and 12-13 days for the patients with chronic maxillary sinusitis.

## 2.4 Light source

For photodynamic treatment of maxillary sinusitis the AFL-1 laser system (Russia) was used. The GN-80 He-Ne laser ( $\lambda = 632.8 \text{ nm}$ ) (Russia) with an originally designed fiber-optic diffuser. Diameter of optical fiber was 0.9 mm with core diameter 400  $\mu\text{m}$ . The power of the laser system on the fiber tip was 40 mW. Since area of one maxillary sinus varied from 14.6  $\text{cm}^2$  to 29.2  $\text{cm}^2$ , the power density varied from 1.4 to 2.7  $\text{mW}/\text{cm}^2$  within the sinus.

## 2.5 PDT protocol for treatment of sinusitis

For PDT the following protocol has been used. Before the treatment the puncture of maxillary sinus through the nasal duct was made with standard aspirating needle. Then catheter with diameter 1 mm was injected through the needle. The lavage of maxillary sinus of a patient was performed by physiological solution with the use of the catheter, and after that 1.5 ml of the aqueous 0.1%-MB (Sigma, USA) solution was administered into the maxillary sinus. For the patients with chronic maxillary sinusitis persistent drainage was carried out in 10 days during the treatment. The staining time was 30 min. Before irradiation the lavage of maxillary sinus of the patient by physiological solution was again performed.

Laser radiation was delivered into the maxillary sinus by optical fiber with the fiber-optic diffuser through the catheter. The exposure time was 15 min per treatment procedure. Dose of one irradiation was 1.3–2.4 J/cm<sup>2</sup>. Course of treatment was 1-5 procedures for the patients with acute maxillary sinusitis and 3-8 procedures for the patients with chronic maxillary sinusitis. Total dose of the irradiation was 1.3–19.2 J/cm<sup>2</sup> in dependence on number of the PDT treatments.

## 2.6 Testing of recovery

The differences between the results of the treatment with dye and light versus treatment with drug for every group of patients were statistically analyzed by the Student's *t*-test. A *P* value of less than 0.05 was taken to indicate statistical significance. Efficacy of the PDT was estimated with the use of the following criteria: the state of nasal breathing, olfaction, duration of purulent discharge, reconstruction of transport function of ciliary epithelium, transparency of paranasal sinus (X-ray photography), and hospital stay. Estimation of common blood analysis was made from the index of erythrocyte sedimentation rate and the change of leukogram.

## 3. RESULTS

### 3.1 Microbiological analysis

As a result of microbiological examination different pathogens were detected. Main agents leading to the sinusitis development were: *staphylococcus*, *streptococcus* and *proteus vulgaris*. Data of the microbiological analysis for the patients with acute and chronic maxillary sinusitis are presented in table 2. In the table it is seen that 6.7% of smears from medial nasal duct and 10.7% of smears from maxillary sinuses showed lack of bacterial growth.

Table 2. Data of the microbiological analysis for the patients with acute and chronic maxillary sinusitis

Forms of microflora	Frequency of finding, %			
	Acute maxillary sinusitis		Chronic maxillary sinusitis	
	Medial nasal duct	Maxillary sinus	Medial nasal duct	Maxillary sinus
<i>Staph. aureus</i>	26,3	21,5	21,3	22,6
<i>Str. heaemoliticus</i>	18,5	3,0	18,7	-
<i>Staph. epidermidis</i>	15,4	16,9	18,7	16
<i>Staph. saprofiticus</i>	4,6	-	2,6	-
<i>Str. pyogeneus</i>	7,6	9,2	10,7	9,3
<i>Str. viridans</i>	6,2	10,8	8	12
<i>Pr. vulgaris</i>	-	-	-	9,3
<i>Str. pneumoniae</i>	7,6	18,5	9,3	20,1
<i>E. Coli</i>	1,6	1,6	-	-
<i>Cand.+ Staph.</i>	4,6	-	4	-
Lack of growth	7,6	18,5	6,7	10,7
Total:	100	100	100	100

In all groups plates showed lack of growth after the treatment.

### 3.2 The treatment of patients with acute maxillary sinusitis

Signs of clinical recovery of the patients were defined in accordance with data of objective research. At the rhinoscopy the reduction of swelling and hyperemia of a mucous membrane and decrease of periosteal reaction at the palpation in the region of nasal cavities were observed. Restoration of olfaction and transport function of ciliary epithelium was registered. Besides X-ray data about the state of nasal cavities, the state of peripheral blood, normalization of a body temperature and duration of stay of patients in a hospital were considered.

Results of the observations on the patients with acute maxillary sinusitis from both groups PDT and control during the treatments have shown that recovery of all clinic signs took place faster for the first group (PDT) than for the second group (traditional therapy). So, nasal breathing improved after  $5.0 \pm 0.2$  days for the first group and  $6.1 \pm 0.3$  days for the second group. Recovery of olfaction was observed in  $4.2 \pm 0.2$  days and in  $5.1 \pm 0.2$  days, respectively. The presence of purulent discharge was not observed after  $4.2 \pm 0.3$  days of the PDT treatment and after  $6.2 \pm 0.3$  days of the pharmaceutical treatment. Recovery of the transport function of ciliary epithelium took place during  $6.2 \pm 0.2$  and  $7.1 \pm 0.2$  days. More significant differences in the period of recovery were observed for the transparency of paranasal sinus obtained from X-ray photography:  $10.1 \pm 0.3$  and  $13.2 \pm 0.3$  days for the first and the second groups, respectively. Thus, average duration of hospital stay for the patients treated with PDT therapy was only  $10.6 \pm 0.3$  days, while for the patients treated with traditional method it was  $12.6 \pm 0.4$  days. Comparison of the values of the clinical signs using the Student's *t*-test has shown that the differences in the data between two groups of the patients were statistically significant ( $P < 0.05$ ). All data are presented in figure 1.

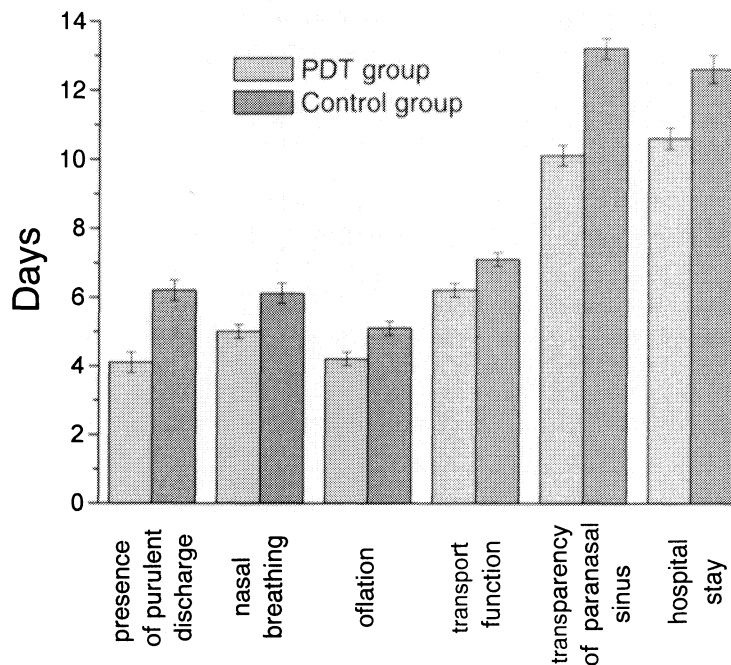


Figure 1: The clinical signs of patients with acute maxillary sinusitis

In the study of peripheral blood of patients before and after the treatment significant differences of indexes of peripheral blood between both groups was not observed. It has shown that PDT did not have apparent influence on the hematopoietic function of the organism.

The results of the treatment were evaluated during total course of the therapy and in prolonged period (two years) after that. They have demonstrated beneficial effect of PDT on the inflammation process; positive dynamics was observed in

100% of cases for patients with acute maxillary sinusitis. Catamnesis observations on the 37 patient have shown that in the PDT group relapses took place in 11.1% of cases, and in the control group there were in 26.3% of cases.

### 3.3 The treatment of patients with chronic maxillary sinusitis

All patients with chronic maxillary sinusitis were required more prolonged course of PDT treatment for relief of symptoms of the disease than the patients with acute maxillary sinusitis.

For patients with chronic maxillary sinusitis recovery of nasal breathing was observed after  $7.3 \pm 0.2$  days of PDT treatment. In the control group the recovery was observed only after  $8.7 \pm 0.3$  days of the pharmaceutical treatment. In both groups recovery of olfaction took place after  $6.1 \pm 0.3$  days of the treatment. The presence of purulent discharge was not observed after  $7.1 \pm 0.3$  days of the PDT treatment and after  $8.1 \pm 0.3$  days of the pharmaceutical treatment. Recovery of the transport function of ciliary epithelium was observed after  $6.2 \pm 0.2$  days and  $7.1 \pm 0.2$  days for the first and the second groups, respectively. The period of recovery of the transparency of paranasal sinus was not fixed because total recovery of the transparency at the chronic sinusitis was not observed in the both groups. Hospital stay was  $13.4 \pm 0.3$  days for patients treated with PDT therapy and  $15.7 \pm 0.4$  days for patients treated with pharmaceutical therapy. Data with the signs of clinical recovery of the patients are presented in figure 2.

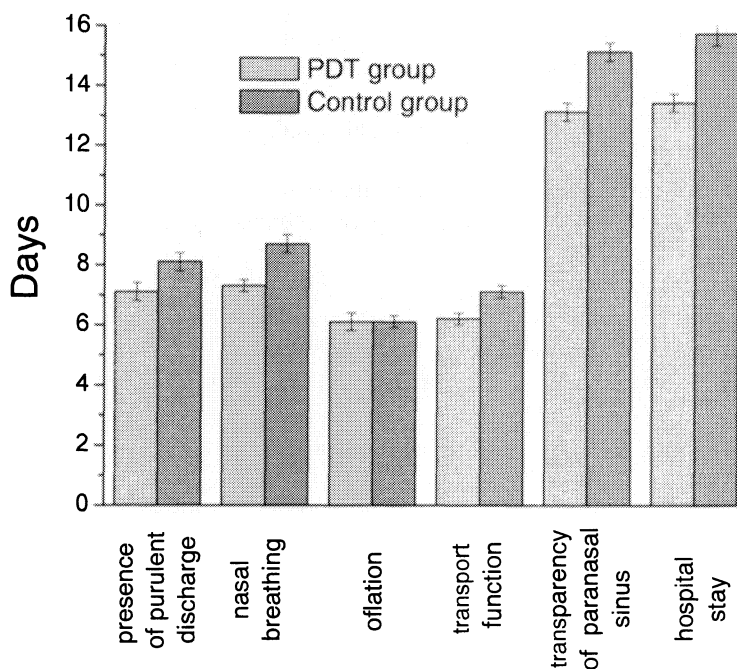


Figure 2: The clinical signs of patients with chronic maxillary sinusitis

At the application of the PDT for treatment of patients with chronic maxillary sinusitis the full recovery was observed for 54.3% of patients. In control group the full recovery was observed for 50% patients. Satisfactory results (insignificant difficulty at respiration, etc) were observed for 31.4% of patients from the first group. In the second group the satisfactory results were observed for 27.5% of patients. Non-satisfactory results were obtained for 14.3% of patients from the first group, and for 22.5% patients from the second group. In the cases the patient complaints were difficulty in nasal respiration and purulent discharge. Such patient had been made surgery of maxillary sinus. The observations during two years after the treatment have shown efficacy of PDT for treatment of patients with chronic maxillary sinusitis. Positive dynamics was observed in 85.7% of cases. For the patients treated with traditional therapy it was only in 77.5% of cases.

Analysis of peripheral blood before and after the treatment have shown that PDT did not influence the hematopoietic function and did not have sensibilizing action of the organism.

Catamnesis observations during two years on 44 patients have shown that in the PDT group relapses took place in 55.5% of cases, and in the control group there were in 82.3% of cases.

### ACKNOWLEDGMENTS

The research described in this publication has been made possible, in part, by grant REC-006/SA-006-00, Annex N. 07 "Nonlinear Dynamics and Biophysics" of U.S. Civilian Research and Development Foundation for the Independent States of the Former Soviet Union (CRDF) and the Russian Ministry of Science and Education and the Russian Federation President's grant N 25.2003.2 "Supporting of Scientific Schools". The authors thank Dr. S.V. Eremina (Department of English and Intercultural Communication of Saratov State University) for the help in manuscript translation to English.

### REFERENCES

1. E.P. Stranadko, A.V. Ivanov, "Photodynamic therapy in cancer and nontumor diseases," *Biophysics*, **49**, 380-383, 2004.
2. F.S. de Rosa, M.V.L.B. Bentley, "Photodynamic therapy of skin cancers: sensitizers, clinical studies and future directives," *Pharmaceutical Research*, **17**, 1447-1455, 2000.
3. M.K. Fehr, R. Hornung, A. Degen, V.A. Schwarz, D. Fink, U. Haller, P. Wyss, "Photodynamic therapy of vulgar and vaginal condyloma and intraepithelial neoplasia using topically applied 5-aminolevulinic acid," *Lasers Surg. Med.*, **30**, 273-279, 2002.
4. H. Koren, G. Alth, "Photodynamic therapy in gynaecologic cancer," *J. Photochem. Photobiol. B*, **36**, 189-191, 1996.
5. G. Koderhold, R. Jindra, H. Koren, G. Alth, G. Schenk, "Experiences of photodynamic therapy in dermatology," *J. Photochem. Photobiol. B*, **36**, 221-223, 1996.
6. V.V. Tuchin, E.A. Genina, A.N. Bashkatov, G.V. Simonenko, O.D. Odoevskaya, G.B. Altshuler, "A pilot study of ICG laser therapy of *acne vulgaris*: photodynamic and photothermolysis treatment," *Lasers Surg. Med.*, **33**, 296-310, 2003.
7. T. Kormeili, P.S. Yamauchi, N.J. Lowe, "Topical photodynamic therapy in clinical dermatology," *Br. J. Dermatol.*, **150**, 1061-1069, 2004.
8. E.A. Genina, A.N. Bashkatov, G.V. Simonenko, O.D. Odoevskaya, V.V. Tuchin, G.B. Altshuler, "Low-intensity indocyanine-green laser phototherapy of *acne vulgaris*: pilot study," *J. Biomed. Opt.*, **9**, 828-834, 2004.
9. A.N. Nasedkin, V.G. Zenger, S.V. Grachev, V.M. Isaev, E.I. Prokof'eva, V.N. Selin, I.V. Leskov, A.V. Reshetnikov, I.D. Zalevskiy, S.E. Goncharov, Yu.V. Kemov, "The experience of application of photodynamic therapy for treatment acute and chronic purulent antritis," *Russian Rhinology*, **2**, 116, 2002.
10. A.N. Bashkatov, E.A. Genina, V.I. Kochubey, V.V. Tuchin, E.E. Chikina, A.B. Knyazev, O.V. Mareev, "Optical properties human maxillary sinus mucosa and estimation of Methylene Blue diffusion coefficient in the tissue," *Proc. SPIE*, **5771**, 316-327, 2005.
11. K. Orth, G. Beck, F. Genze, A. Ruck, "Methylene blue mediated photodynamic therapy in experimental colorectal tumors in mice," *J. Photochem. Photobiol. B*, **57**, 186-192, 2000.
12. I.D. Botterill, P.M. Sagar, "Intra-dermal methylene blue, hydrocortisone and lignocaine for chronic, intractable pruritus ani," *Colorectal Disease*, **4**, 144-146, 2002.
13. M.C. Teichert, J.W. Jones, M.N. Usacheva, M.A. Biel, "Treatment of oral candidiasis with methylene blue-mediated photodynamic therapy in an immunodeficient murine model," *Oral Surgery, Oral Medicine, Oral Pathology, Oral Radiology & Endodontics*, **93**, 155-160, 2002.
14. G.Z. Piskunov, S.Z. Piskunov, *Clinical Rhinology*, Moscow: Miklon, 2002 (in Russian).